

USDA Inspection Report Quotes: Examples of Severe Violations

The quotes below are excerpts from inspection reports on licensed dog breeders (Class A) and dog dealers (Class B) acquired by The HSUS from the United States Department of Agriculture (USDA) between 2015 and 2020. The information was found via online inspection report database searches or acquired through open public records requests. Some licenses have been cancelled since the information was first gathered. Cancellation dates are noted if known. When a license is listed as cancelled, it is unknown whether the operator discontinued the license voluntarily or involuntarily. Some operators who are no longer licensed by the USDA may still be in business




PHOTO BY USDA- CONNIE WEST, 2019

selling puppies directly to the public, and some remain licensed by their individual states. The sale of puppies directly to the public does not generally require a USDA license but may require a state license in some states.

Yellow highlighting was added by HSUS for ease of reference. Highlighting was not a part of the original reports.

ARKANSAS

“A female Yorkshire Terrier, named Paige (4972166F17), had a collar hooked under her right front leg. When the collar was removed, inspectors noticed that the collar had rubbed a deep, open laceration into the right armpit, approximately 2 inches long and 1 inch wide.”

- USDA inspection of Frank Peck, Mountainburg, AR- 71-B-0150, Dec. 6, 2017 (USDA license cancelled in Sept. 2019)

“Upon entering the puppy building the inspector noticed a strong odor of dog feces and urine. After about ten minutes the inspector could feel a burning in the eyes and back of the throat from the odor and ammonia. Two adult dogs were observed with tearing of the eyes which could be attributed to the strong odor...”

“A six year old, female, black and tan Yorkshire terrier [...] was observed spinning in its enclosure almost continuously for the duration of the time we were in the building about one hour. This is not normal behavior and can be a sign of physiological distress.”

- USDA inspection of Jamark, Paris, AR- 71-B-1303, May 17, 2017

FLORIDA

“An adult female English Bulldog was not given adequate veterinary care when it was injured two weeks ago. This dog was injured while climbing underneath the chain link fencing located in an outside exercise pen. The center of the wound is approximately 1/2” deep and 3” to 4” long and an inch wide.”

- USDA inspection of Beverly Hills Puppies Inc, Miami / Hialeah, FL- 58-B-0615, Feb. 7, 2017

“During this inspection of this kennel on June 28, 2017, and June 29, 2017, there were excessive amounts of excreta in most of the dog enclosures. There were from 3 to 5 occurrences or more of fecal waste in each enclosure. I observed numerous dogs many in the smaller top kennels stepping in the excreta and on their wood platforms....During the inspection on June 29, 2017, the primary enclosures were observed being cleaned with a pressure washer without the excreta [being] completely cleaned first. This method of cleaning spreads excreta particles throughout the kennel where other dogs could potentially spread infectious bacteria and viruses.”

“The ambient temperature in the indoor kennel was 99.6 F, with high humidity level of 70%. Most all of the dogs during this inspection were panting, some heavier than others. [...] During the inspection on June 29, 2017, at 1230 pm, the ambient temperature was from 98.7 F and 99.6, with a high humidity level of 75%. Again most the dogs were panting some heavier than others. The adult female English Bulldog Elizabeth (#9000850000072610) was panting laying down in the kennel with foam around her mouth and on the floor from heavy salivation.”



PHOTO BY USDA- BEVERLY HILLS PUPPIES, 2017

- USDA inspection of Beverly Hills Puppies Inc, Miami/Hialeah, FL- 58-B-0615, June 28, 2017

GEORGIA

“A pregnant Great Dane in the large dog whelping building is excessively thin. Her spinal vertebrae, ribs, scapula, and pelvic bones are easily visible.”

- USDA inspection of Judy Hulett, Rhine, GA- 57-A-0206, Mar. 5, 2019

ILLINOIS

“One eight-week-old female yellow Labrador Retriever (#18-7-2) was observed to be lying on its side, breathing very slowly and not moving. The puppy appeared to be close to death, as it did not respond to stimulation around it, including lack of response to flies landing on its body and the loud barking of nearby dogs.”

- USDA inspection of Howard E. Yoder and Lamar J. Yoder/Memory Lane Kennel, Arthur, IL- 33-A-0583, July 19, 2018

INDIANA

“During a focused inspection conducted August 24, 2017 a puppy was observed drowned in its water bowl. This small, eight week old, female, American Eskimo puppy was observed singly housed yesterday. Today, it shared an enclosure with a fully grown, approximately 35 pound, female Shiba Inu mix. The puppy was fully submerged in blood tinged water, eyes bulging, with agonal convulsions when this inspector pulled her out of the water bowl. It was too late, she was dead. The puppy had bloody bite wounds on her head and body. The Shiba Inu had blood on its chest. It is unknown exactly how the puppy ended up in the water bowl, or if she was alive prior to entering the water. Regardless of these details, clearly this young puppy was attacked by the older adult dog resulting in her death.”

- USDA inspection of Daniel S. King / Long Lane Kennel, Greens Fork, IN- 32-A-0504, Aug. 24, 2017 (USDA license cancelled in May 2017)

“At 5 pm, the temperature during the inspection outside of the kennels was 92 deg F. The temperature inside of the whelping kennel was 89 deg F, with a Heat Index of 103 deg F. [...] The dogs in both sheltered kennels, were panting heavily throughout the inspection. This is a ‘short nosed’ breed that has difficulty moving air and are very susceptible to respiratory distress from heat stress when environmental temperatures are high. There was a female nursing her pups, who was lying flat out and panting heavily (signs of heat stress). The neighboring enclosure contained 8 pups that were lying on their back and side, separated from each other and panting, so they were also showing signs of heat stress.”

- USDA inspection of Ivan and Malinda Kay Graber, Odon, IN- 32-A-0484, Sept. 21, 2017 (USDA license cancelled in Nov. 2018)

“A crème female wheaten terrier, # 569, was observed hunched over in her kennel. Further observations revealed she had a softball sized vaginal prolapse. Approximately 2-3 inches of the vagina were extending outward from the vulvar opening. Treatment log records indicated that the prolapse was observed by the licensee on May 23rd, 2019. A discussion with the attending veterinarian, after completing the kennel inspection, revealed that she was unaware of the prolapsed vagina.”

“The whelping building consists of raised kennels over a concrete wash-down. The wash-down gutter was full of feces, old food, and maggots. A strong ammonia odor was observed upon walking up to the facility. Additionally, there were a significant amount of flies.”

- USDA inspection of Wayne Miller, Middlebury, IN- 32-A-0479, July 8, 2019 (USDA license cancelled in Nov. 2019)

IOWA

“Female Shiba Inu puppy (#116) was observed vomiting a yellow liquid. After vomiting, the puppy wrinkled up the sides of her snout and kept her eyes mostly closed. The puppy maintained this appearance throughout the time it was evaluated. The puppy acted lethargic and when removed from the enclosure she hung limply when held.”

- USDA inspection of Steve Kruse / Stonehenge Kennel, West Point, IA- 42-B-0182, Sept. 19, 2016

“Female Shiba Inu (#25) is non-weight bearing in the right front leg. Closer examination of the leg showed a ruptured lesion on the bottom of the foot between the second and third digit pads and the main foot pad. The lesion is red, inflamed, warm to the touch, and a clear, sticky fluid is matted into the hair around the lesion.”

“Female Woodle (#8) is hesitant to rise into a standing position. When attempting to get into a normal posture the dog was unable to bear full weight on the right hind leg and showed obvious lameness while walking. Closer examination showed the dog was very tense when the lower back, the hip, and the bottom of the right hind foot were gently palpated. The dog is not currently under any treatment for this condition. Female Bichon (#7) has an abnormal appearance when she walks. She appears to stand and walk in an arched position. Upon palpation the dog was found to be tense in her mid and lower back. The dog is not currently under any treatment for this condition. Female Bulldog (#7) is lame in the left front leg. Closer examination did not reveal the cause of the lameness and this dog is not currently under treatment for this condition. Female Wheaton (#127) is lame in the right hind leg. Closer examination showed that the dog wanted to pull away when the leg was gently palpated, but no cause for the lameness was found. The dog is not currently under treatment for this condition.”

- USDA inspection of Steve Kruse / Stonehenge Kennel, West Point, IA- 42-B-0182, Dec. 10, 2019

“The first building, housing approximately thirty-one adult dogs, has an ambient indoor temperature of 91 degrees F and a heat index up to 108.4 degrees F according to the Kestrel. The majority of the adult dogs are showing signs of heat stress such as open mouthed breathing, an increased respiration rate, and heavy panting with their tongues extended from their mouths.”

“The second building, housing approximately thirty adult dogs and forty puppies, has an ambient indoor temperature of 94 degrees F and a heat index up to 109.7 degrees F according to the Kestrel. The majority of the adult dogs are showing signs of heat stress such as open mouthed breathing, increased respiration rate, and heavy panting with their tongues extended from their mouths. All the litters of puppies are spread out around their enclosures and one four and a half week old puppy was observed to be panting and has an increased respiration rate.”

- USDA inspection of Eli H. Mullett, Cantril, IA- 42-A-1548, June 18, 2018 (USDA license cancelled in Sept. 2019)

“In the “Female Building” there are plastic feeders used to provide dog food to the dogs. In at least three of these feeders insects are found in and under the dog food. The insects consist of live maggots, live beetle larva, skins of larva that had pupated, and at least one live adult beetle.”

- USDA inspection of Helene Hamrick / Wolf Point Kennel, Ackworth, IA- 42-A-0124, June 19, 2017

“In the outdoor section of one enclosure is a deceased female Chihuahua (microchip #0007296B3B). The dog is located at the end of the enclosure lying on her right side up against the enclosure gate. There is a large, circular open wound in the lower left side of the abdomen directly in front of the left hind leg. The licensee said this dog tended to have intermittent issues with uterine infections during the time she has been at the facility.”

- USDA inspection of Jonathan Yutzy, Bloomfield, IA- 42-A-1467, Sept. 12, 2017 (USDA license cancelled in Apr. 2018)

“At the time of the inspection the outdoor temperature is 7 degrees according to the weather channel internet site (weather.com) and the water in the majority of the outdoor water receptacles was completely frozen solid. In one outdoor enclosure, one Great Dane was observed licking the snow and the other Great Dane was observed licking the ice in the water receptacle. The facility representative was asked to provide the dogs with water and the dogs drank enthusiastically for approximately 1 minute and 12 seconds.”

- USDA inspection of David, Glenda, Eric and Adam Grove / Iowa Fox Creek Kennels, Unionville, IA- 42-A-1093, Jan. 16, 2018

“A female Dachshund puppy (DOB 02/06/2016) has hair loss on her head, snout, ears, around her eyes, and on her legs and feet. The skin in the hairless areas on her head, snout, eye area and ears has thickened and become crusty and flaky. There is a buildup of a yellowish crusty material around the lower lid of the right eye and there are strands of the yellowish material from the top eye lid attached to the bottom eye lid. The inside of both ears have thick, dark colored material surrounding the ear opening. Both ears have a white/yellowish colored discharge coming from them and the inside of the left ear is moderately reddened. The inspector noticed that the puppy seemed lethargic and cried out when she was touched.”

- USDA inspection of Captiva Kennel Inc, Redding, IA- 42-A-1319, May 18, 2016 (USDA license cancelled in Oct. 2017)

KANSAS

“The licensee stated that a little over a year ago two old, nonproductive dogs euthanized by gun shot. The licensee also stated that a neighbor (unidentified by licensee) disposed of three more dogs. The licensee stated that they had no idea how the three dogs were euthanized. The licensee stated that the dogs are currently buried on the premise. When asked why the licensee euthanized the dogs by gun shot, the licensee responded they had a right to dispose of the dogs anyway they desired.”

- USDA inspection of Virginia Hinderer / Dusty Road Kennel, Wakarusa, KS- 48-A-2139, Sept. 20, 2017 (USDA license cancelled in Oct. 2017)

“Male, adult Akita [...] has hair loss on both sides of his body, along the length of his back and on the outsides of his thighs. The exposed skin and the haired skin along his backbone and shoulders has a thick, scaly appearance in places. There is some fresh blood on the right side of the hairless area.”

- USDA inspection of Joyce Cairns / Unicorn Kennel, Glasco, KS- 48-A-1027, July 5, 2018

“Pebbles” is an adult, male parti-colored Poodle with no identification number. When the enclosure was first approached, inspectors noticed this dog was quietly curled up in the corner while the other dogs housed with him barked and ran around. The dog was reluctant to have his mouth handled and initially pulled his head away. There are open holes in the upper gums where the canine teeth used to be. In addition, the lower jaw bone felt “soft” and could be moved side to side gently and slightly.”

- USDA inspection of Connie Fahey / Connie’s Puppies, Clyde, KS- 48-A-2194, Dec. 6, 2017

MISSOURI

“There were 5 un-weaned pug puppies that were born 2/11/2016. The cage card on the outside of the enclosure listed that the dam had given birth to 7 puppies and 3 of the puppies were noted to be deceased. While the licensee had not recorded the dates the puppies had died she stated that they were at least two weeks of age when they died. She described the puppies as being smaller in size than the rest of the litter but was unsure [of] the reason for death as they were never evaluated by a veterinarian or provided additional care. One of the 5 remaining puppies was ½ the size of its litter mates and appeared lethargic and weak. Its litter mates chewed on its ears and repeatedly climbed over its body rolling the smaller puppy around while it remained motionless. When the inspector asked the licensee why there were 7 puppies listed on the cage card, 3 of which were marked as deceased and there were 5 puppies remaining, the licensee and staff explained that they ‘expected the small puppy to die soon.’ The licensee and staff were not providing any individualized or veterinary care to the puppy.”

“On 3/2/2016 an adult English bulldog named ‘Casper’ was taken to the attending veterinarian for a lack of appetite. The veterinarian documented the animal as having a body condition score of a 3/9 and confirmed the dog was positive for whipworms. The licensee was instructed to provide Fenbendazole, clean and feed a high protein diet. The licensee stated she provided Fenbendazole for 6 days, as well as feeding the dog raw hamburger on the 6th day. On the 7th day, the dog was found dead with blood draining from its rectum. Upon further inspection it was discovered that the licensee had been mixing her own Fenbendazole wormer by using a large tube of [cattle wormer] and diluting it with tap water. The licensee had no formal instructions for adding water to the worming mixture and the attending veterinarian had not authorized its use. Mixing or diluting medications can alter their desired effect and potency.”

- USDA inspection of Wilma Jinson / Jinson Kennel, Stella, MO- 43-A-2656, March 14, 2016 (USDA license revoked in Sept. 2016)

“A female Pomeranian and three of her puppies were housed in an indoor enclosure within the whelping building. The puppies were observed lying inside of [an empty metal water bowl]. There were no other sources of water provided inside of the enclosure. During the inspection around 1:45 pm, the inspectors asked a facility representative to fill the receptacle with water. After the bowl was placed inside of the enclosure for the dam and her puppies, the dam was observed to immediately start drinking from the bowl continuously for over 1 ½ minutes. [...] When asked about the last time the dogs had been given water, the licensee stated that they had all been given water yesterday evening.”

“An enclosure within the whelping building housing three Saint Bernards and one Boxer had an accumulation of fecal material in the outdoor portion of their enclosure that was mashed, smeared and splattered which covered most of the entire outdoor flooring. The dogs in this enclosure, with ages around 3 to 6 months old, also had the fecal material visible on their hair coats including on their paws, legs, tails, sides and backs..”

- USDA inspection of Cory Mincey / Cory’s Cuties, Elkland, MO- 43-A-5947, Nov. 2019 (USDA license cancelled in Dec. 2019).



PHOTO BY USDA- CORY MINCEY, 2019

“A Bernese Mountain dog had a bloody area on its back due to a nest of ticks.”

- USDA inspection of Joe Farley / Pleasant Valley Puppies, Galena, MO- 43-A-6006, July 24, 2019

“A litter of eight Weimaraner puppies born on 06/04/19 were undersized for their age and underweight. They were lethargic and had many ticks on them. All of the puppies were thin with three of the puppies having visible ribs and hip bones. One of these puppies was extremely weak, had difficulty standing, and had visible shoulder and vertebral bones. The puppies were housed in an outdoor enclosure. The puppies had not received any type of supplemental nutrition or husbandry. A veterinarian had not been consulted about their condition.”

“An adult female Weimaraner named “Daisy” (m/c 941000014976966) had ticks covering most of its body. Many of the ticks were engorged.”

- USDA inspection of Joe Farley / Pleasant Valley Puppies, Galena, MO- 43-A-6006, July 9, 2019

“The licensee had written instructions from her Attending Veterinarian on how to dock puppy tails. These instructions included removing the tail with Metzenbaum scissors or a Carmalt clamp and then apposing the skin edges with sutures or tissue adhesive. The licensee was removing the tails by twisting them off and then applying blood clotter without apposing the skin.”

- USDA inspection of Joe Farley / Pleasant Valley Puppies, Galena, MO- 43-A-6006, Feb. 23, 2016

“Female Shih Tzu #163 had pink tissue about the size of a pea near the tear duct area of the right eye, protruding out onto the eye. On this same dog, the ID chain was tight and had caused sores around the dogs

neck. These sores were open lesions under the chain, and reddish skin around the same areas as the lesions. There was also blood like matter on the left side of the dog between the ear and front shoulder. The hair was missing around the neck in the area of the chain and lesions. The lesions were about 1/4" - 1/2" wide and circling the neck."

"A female Maltese #142 was limping on its right front leg. After the licensee pulled the dog out, the inspector pointed out to the licensee, the right foot (wrist area) could easily be felt moving in a direction that is not the normal direction the foot should move."

- USDA inspection of Albert J. Troyer, Clark, MO- 43-A-6158, June 21, 2017

"At time of inspection two adult Shar-Pei's were housed together. Shar-Pei (# 000003236385) appeared and felt thin, with a defined waist and visible rib cage. She had blood matting down the hair around her right ear and fresh lacerations (approximately 1 1/2 in. long, with a loose skin flap hanging) on the lateral aspect of both hind legs."

- USDA inspection of Kimberly Coleman / TLC's Kennel, Clinton, MO- 43-A-4973, Feb. 9, 2017 (USDA license cancelled in Nov. 2019)

"An adult female Poodle named Posey was lying on her side in an enclosure with three other adult dogs. She did not move her legs or appear able to rise. When the licensee attempted to pick her up she appeared painful and snapped at the licensee who had to wrap her in a towel to be able to pick her up. Even when she was removed from the enclosure, the dog made no effort to stand or use her legs. There was blood covering the back half of her body and what appeared to be bite wounds on her legs and back."

- USDA inspection of Kimberly Coleman / TLC's Kennel, Clinton, MO- 43-A-4973, Sept. 22, 2016 (USDA license cancelled in Nov. 2019)

"In the outdoor run portion of the whelping facility, 4 enclosures housing 4 adult female dogs, including 2 with litters, has excreta and dried fecal residue on 70 to 80 percent of available surface flooring. One outdoor enclosure has a mound of feces at least 10" high in the middle of the outdoor enclosure."

- USDA inspection of Pamela L. Baldwin / Samples Creek Kennel, Edgar Springs, MO- 43-A-4762, Jan. 18, 2018 (USDA license cancelled in Dec. 2018)

"The female Dachshund [...] was removed from her enclosure to examine her teeth. Upon examination the dog had a thick, blood-tinged, gray discharge coming from a surgery site on the abdomen. The licensee explained the dog underwent a Cesarean-section a week prior. Even though the sutures were intact, the edges of the skin were not apposed."

- USDA inspection of Lynn Sartin, Granby, MO-43-A-4843, Aug. 23, 2017

"A white and golden male Lhasa Apso, microchip #0A02201909, was initially observed with a large lesion on the right side near its shoulder. On closer observation the lesion on the right side appeared to be a large healed scar. While the licensee was holding the dog, he was asked to move his hand so the left side of the dog's neck could be viewed. The dog had a wound located on the left side of his neck. An approximately 2 inch open linear laceration-like lesion was noted on the neck. The wound was open with exposed red tissue underneath and a thick creamy whitish discharge was present in and around the lesion. Fur was present up to the open wound and did not appear clipped. The surrounding fur immediately around the wound and extending down the neck was discolored black and significantly matted. Some of the visible skin under the fur in this area appeared reddened. The licensee seemed surprised at first that a wound was present on the left side of the dog's neck."

- USDA inspection of Donald Schrage / Rabbit Ridge Kennel, Edina, MO- 43-A-1957, June 2, 2016 (USDA license revoked in Jan. 2017)

“During the inspection heard puppy whining and looked into enclosure and seen the left front leg missing fur and the mother was grooming the puppy. The puppy number is 2016-69 a cavalier/poodle mix. I asked licensee to pull the puppy out of pen to better observe the puppy, that is when I saw the rear paws missing fur and the affected areas are red and a cream colored puss like material observed in the affected areas. Licensee said the mom killed the other puppy and asked if its time to retire the mom.”

- USDA inspection of Debbie Howlett / Luv Me Tender Kennel, Bolivar, MO-43-A-5888, Apr. 19, 2016 (USDA license cancelled in July 2018)

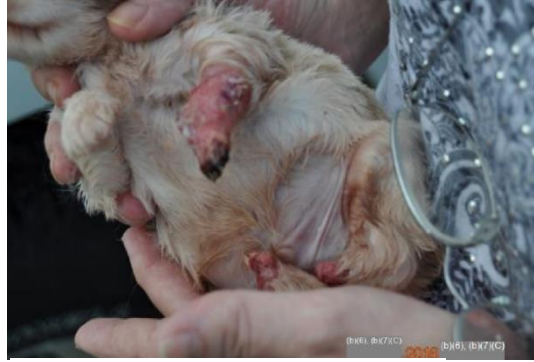

PHOTO BY USDA- Debbie Howlett, 2016

“There was an excessive amount of feces in about 25% of the enclosures, and excessive build-up of feces on the wash downs under the enclosures. The fecal build-up in the enclosures was enough where the dogs could not move around freely without stepping in it. The wash downs were full of fecal material covering most of the wash down with a several inch thick layer.”

- USDA inspection of David Miller/Shady Kennels LLC, Keytesville, MO- 43-A-6362, March 7, 2019

NEW YORK

“On 2-Jun-2019 the dog identified as #21 (Brenda) was observed by licensee during his evening husbandry to be in labor but making no progress delivering her pups. She subsequently died later that evening without delivering her litter. The attending veterinarian was not consulted before or after the dog’s death and the licensee stated he was unaware that the attending veterinarian provided emergency and after-hours care and therefore he did not attempt to call the attending veterinarian.”

- USDA inspection of Levi O. Hershberger, Woodhull, NY- 21-A-0194, Dec. 11, 2019

“A Maltese identified as # 93300012017 “Simon” was heavily matted over 90% of his body. The heavy matted fur in the anal region was trapping fecal material making it difficult for the dog to continue to defecate.”

- USDA inspection of Stevie Hoover / Hill Country Kennel, Dundee, NY- 21-A-0191, Oct. 15, 2018

“During the inspection, a litter of puppies was observed with one appearing to be the runt and slightly away from the other puppies. When the puppy was picked up, it was not breathing and was cold to the touch. The licensee stated he had observed the dogs in the kennel that morning and two other individuals were working in the kennel during the inspection process, but none had noticed the puppy was deceased.”

“At the time of the inspection, a litter of 6 week old puppies did not have access to puppy food, as the feeder was too high. One female puppy # 1930 was thin with ribs visible.”

- USDA inspection of Stevie Hoover / Hill Country Kennel, Dundee, NY-21-A-0191, June 3, 2019

“The current outside runs are gravel floor with wire mesh along the sides. The wire mesh is not buried and the dogs are able to dig underneath into adjacent enclosures. A few of the dogs have the ability to jump out of the enclosures and then jump into another dogs enclosure. On May 20, 2018 a Yorkie # 4023 was able to dig underneath into another enclosure and was subsequently killed by a Labrador retriever. At the time of the inspection, several Boston terrier puppies had dug underneath the wire and were in multiple adjacent enclosures housing adult breeding males and females. This is dangerous for these puppies as they could be injured by the adult dogs. In addition, a Jack russel terrier had jumped out of its enclosure, killed a chicken and then jumped into the Boston terrier enclosure and deposited parts of the chicken in with the puppies. There was a large amount of chicken feathers throughout the outdoor run.”

- USDA inspection of Stevie Hoover / Hill Country Kennel, Dundee, NY-21-A-0191, June 20, 2018

OHIO

“Approximately 25% of the adult dogs in the kennel had had their nails excessively short by the licensee. The dogs that were examined appeared sore as they tried to pull their feet back, drooled, attempted to bite the inspector, they licked and chewed their feet and trembled as well as defecated and urinated during the exam. The dogs appeared lame when not directly being observed which was exhibited by being hesitant to bear weight on a limb, licking the feet, and limping. Multiple dogs had feet that were bloody and had blood clots stuck to the feet. The sensitive pulp of the nail was exposed in 24 dogs.”

“The licensee had not identified the dogs with nails that had been cut so short that the feet were bleeding and was not performing any treatment. The licensee stated that the dogs nails had been cut in the morning. The dogs identified by the inspector were actively bleeding at 12pm and many were still bleeding when the inspector returned at 4:45pm.”

- USDA inspection of David D. Miller / Miller Kennel, Millersburg, OH- 31-A-0482, July 31, 2017 (USDA license cancelled in Mar. 2018)

“Dog #54, a Boston Terrier female, has a large open lesion on her right side that is about 2” wide and about 5” long starting at the base of her neck to about $\frac{3}{4}$ of the way down her side and shoulder area. The lesion is wet with an area of the wound, approximately 1.5 x 2.5 inches in diameter, that is dark red, crusted, and sloughing exposing the underlying tissue.”

- USDA inspection of Abe Yoder / Woodside Kennel, Millersburg, OH- 31-A-0710, Oct. 3, 2018 (USDA license cancelled in Feb. 2019)

“On today’s inspection, a white female chaweenie puppy born on 8/12/2019 was noticed to be sitting in the corner of the whelping box as its litter mate ran around. After watching the puppies for a few minutes, it was apparent that the puppy was not moving or as active as the other puppy due to an impairment of her hind legs. She would try to move around, but was unable to rise to her feet as her legs remained curved up under her, stiff and non-weight bearing. She would inch around on her belly after several attempts to use her hind legs. At one point the Licensee tried to coax the puppy to move and she cried out after several attempts of being unable to rise to her feet and walk. There was a total of 4 puppies in this litter, 2 of the litter mates are identified on the cage card as dying from unknown causes on 8/20/2019. The Licensee did not communicate with the Attending Veterinarian after $\frac{1}{2}$ of the litter died un-expectedly 8 days after birth. In addition, the Licensee did not notice the hind leg issue with this puppy.”

- USDA inspection of Alvin Hershberger / Hill Top Puppies LLC, Patriot, OH- 31-A-0589, Sept. 23, 2019

“Dog with Microchip number 1221389 was noticed to have blood on her hind legs. Upon further examination, there was blood and a thick yellow/green discharge noticed coming from her vulva. The Licensee stated that he had noticed this periodically since she whelped her puppies on 12/3/2018 however; he had not contacted or consulted with his veterinarian.”

- USDA inspection of Steven N. Sauder / Sandy Hill Kennel, Shiloh, OH- 31-A-0631, Dec. 18, 2018

“The male Cavalier had swelling and pronounced recession of the gums, moderate tartar build up and root exposure. The premolars on the left side moved to the touch. The dog allowed his head to be petted but was continuously pulled away when his mouth was touched. Showing discomfort, he pawed at my hand when I was taking photographs. The female Bichon had moderate tartar build up and had upper incisors with pronounced root exposure. Several incisors moved when touched. The gum around the incisors bled when touched. The dog allowed herself to be petted but continuously ducked her head in discomfort and tried to pull away while examining her mouth.”

- USDA inspection of Dennis Hershberger / Hershy Puppy Pals, Charm, OH- 31-A-0212, Dec. 7, 2017

OKLAHOMA

“An approximately 2 year old red female long haired dachshund with no official identification was noticed limping while moving in her enclosure. Upon closer observation inspectors discovered the dog was missing most of her right hind leg. Several inches of a large, dry, yellow-brown bone protruded from the red colored tissue at approximately mid-leg. It appears that all the skin, hair and muscle tissue have been stripped from the bone. The licensee explained that the dog had gotten into a fight with another dog resulting in the loss of the lower part of the right leg. It was not clear how long ago this occurred but based on the appearance of the wound we would estimate several weeks, at a minimum. The licensee also stated that the dog had not been seen or treated by a licensed veterinarian.”

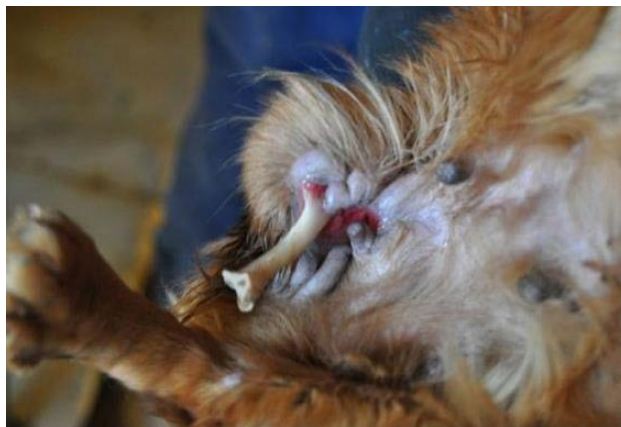

PHOTO BY USDA- Phyllis Burleson, 2016

- USDA inspection of Phyllis Burleson / County Line Kennel, Grove, OK- 73-A-1798, Feb. 18, 2016 (USDA license revoked in Mar. 2016)

“Two litters of puppies were being kept in outdoor housing. Both litters were approximately 1 week old, per facility representative. Temperature for the region at the time of inspection was 36 F. The low temperature in the region for the previous night (October 30) was 32 F. The litter of Labrador puppies were held in a shelter in an outdoor pen. The inner wall of the shelter was measured by IR at 40 F. The litter of Husky puppies were held in an unheated room and located in a corner of the room next to an exposed metal wall with no insulation. All puppies in both litters were tightly huddled together.”



PHOTO BY USDA- Melva Langford, 2015

- USDA inspection of Connie and Jimmy West, Strang, OK- 73-A-1872, Oct. 31, 2019 (USDA license cancelled in Feb. 2020)

TEXAS

“A dead female Italian Grey Hound (#043111029) was discovered in one of the shelters during this inspection. This animal should be taken to the veterinarian for a necropsy in order to determine the cause of death and make certain the cause of death is not a threat to the rest of the dogs in the kennel (infectious disease, etc).”

- USDA inspection of Melva Langford / Broken Spoke Kennels, Whitewright, TX- 74-A-1230, May 28,

2015 (USDA license cancelled in Aug. 2019)

WISCONSIN

“On February 7, 2019 a female Golden Retriever, USDA tag #7, began whelping in the shelter of the outdoor enclosure. The shelter did not have a floor and had several window openings that were not closed up in any way to provide adequate protection from the winter weather conditions. Because the shelter was inadequate, four puppies died of exposure before the licensee realized what was happening and moved the whelping dog into an indoor kennel enclosure where she delivered three more puppies.”

- USDA inspection of Adam and Suzannah Helman, Edgar, WI- 35-A-0429, Mar. 5, 2019



“Female Dachshund, tag #132, cannot weight bear or walk on her left front leg but otherwise appears normal. According to the licensee the dog received an unknown injury to her leg in August 2016 while he was away from his facility. Veterinary care was not provided to the dog by the caretaker at the time of the injury nor the licensee upon his return.”

- USDA inspection of Aaron Hostetler, Stetsonville, WI- 35-B-0208, July 25, 2017

“During inspection, a two week old black and white Boston Terrier puppy was observed to be listless and not moving around much. Upon examination, it felt as if the back of the puppy’s head was swollen and possibly filling with fluid. The licensee stated that this puppy was behaving normally within just the past couple of hours. She stated she had not contacted the Attending Veterinarian as of yet because this was the first she had seen the dog in it’s current condition. I advised her that we should stop the inspection at that point so she could contact the Attending Veterinarian. She responded that there wasn’t much she could do for the puppy and she indicated to me that there was no need to contact the Attending Veterinarian.”

- USDA inspection of Ralph Martin, Thorp, WI- 35-A-0302, Dec. 13, 2017

Find out more information visit humanesociety.org/puppymillresearch

